

# Gastroulcerogenic Evaluation of Ibuprofen Ester Conjugates

*by* Yusnita Rifai

---

**Submission date:** 24-Jan-2023 07:51PM (UTC+0700)

**Submission ID:** 1998414168

**File name:** Rifai\_2019\_J.\_Phys.\_3A\_Conf.\_Ser.\_1341\_072007.pdf (821.9K)

**Word count:** 1994

**Character count:** 11051

PAPER · OPEN ACCESS

## Gastroulcerogenic Evaluation of Ibuprofen Ester Conjugates

To cite this article: Y Rifai *et al* 2019 *J. Phys.: Conf. Ser.* **1341** 072007

View the [article online](#) for updates and enhancements.



**IOP | ebooks™**

Bringing you innovative digital publishing with leading voices to create your essential collection of books in STEM research.

Start exploring the collection - download the first chapter of every title for free.

## Gastroucerogenic Evaluation of Ibuprofen Ester Conjugates

Y Rifai<sup>1</sup>, S Wahyuni<sup>1</sup>, R Yulianty<sup>1</sup> and Y Yusrini<sup>2</sup>

<sup>1</sup>Pharmaceutical Chemistry Laboratory, Faculty of Pharmacy, Hasanuddin University,  
Makassar 90245, Indonesia

<sup>2</sup>Clinical Pharmacy Laboratory, Faculty of Pharmacy, Hasanuddin University,  
Makassar 90245, Indonesia

E-mail : [yusnita@fmipa.unhas.ac.id](mailto:yusnita@fmipa.unhas.ac.id)

**Abstract.** The aim of this study is to search for any potential gastric ulcerogenic properties of the ester form of ibuprofen in comparison with Ibuprofen in order to establish the gastrointestinal safety profile. Ibuprofen ester derivatives were synthesized and were tested for their gastroucerogenic side effects. The esterification of ibuprofen suppressed its gastric ulceration which is associated with its side effect as an antiinflammation. Research results showed that the rat group given Ibuprofen ester conjugate compound had fewer ulcers, smaller ulcer diameters, and less severe ulcer conditions. Histological examination showed that rat in the group given Ibuprofen ester conjugates had lesser number of hemorrhage and congestion compared to the group given ibuprofen. In conclusion, the treatment of Ibuprofen ester conjugates has a lower risk of ulcerogenic effects than the treatment of ibuprofen.

### 1. Introduction

Ibuprofen is a non-selective cyclooxygenase inhibitor which is a phenyl propionic acid derivative. It has an analgesic, antipyretic and antiinflammation properties. Ibuprofen is also used in the treatment of osteoarthritis and rheumatoid arthritis with the mechanism of action by inhibiting both COX-1 and COX-2 [1]. COX-1 serves as cytopathy of gastric epithelium whereas COX-2 is a receptor of inflammation and proliferative disease [2]. Long-term administration of this drug, however, result in side effects such as irritation and ulceration of gastrointestinal mucosa.

Side effects are caused by a direct contact effect produced by free carboxylate groups in the chemical structure of ibuprofen. The presence of carboxylate group produces local irritating effects due to the inhibition of prostaglandin biosynthesis [3]. One way to reduce side effects is modified structures. Chemically modified pharmacologically active drugs that must undergo *in vivo* changes to release the parent drug are one of the development of prodrug. Besides, a computational method is also another way to develop prodrug [4]. The aim of the development of prodrug is to optimize the absorption, distribution, metabolism, excretion, and unwanted toxicity of the parent drug [5].

The development of prodrug is the basis for the development of modified ibuprofen structures. Most modified ibuprofen structures performed on the carboxylic acid chain are the type of ester. This esterification process aims to reduce and suppress gastrointestinal toxicity without affecting the anti-inflammatory activity of ibuprofen [6]. An ester form is the most widely used to prodrug alkyl ester



carboxylic acid. The advantage of using ester is that there is no concern about the toxicity that is part of the prodrug [7].

## 2. Experimental

### 2.1. Material and Methods

Ibuprofen was purchased from Sigma-Aldrich Ltd. (St Louis, USA). Ibuprofen ester conjugates were synthesized and provided in Pharmaceutical Chemistry Laboratory of Hasanuddin university Makassar Indonesia.

### 2.2. Animal and Animal Husbandry

Sprague-Dawley male rats (150-200 grams) were used in the study. The animals were bred in the animal house of Faculty of Pharmacy Hasanuddin University Makassar Indonesia. Laboratory conditions were maintained at a constant temperature of  $2.0 \pm 2.0$  °C on a 12/12 h light/dark cycle. Before the commencement of experiments, animals were allowed to habituate to the laboratory conditions. Rats were not fed both for 4 hours prior to after the administration of the drug until the next day, the feeding and drinking is done ad libitum. Fifteen animals were divided into 3 groups with five animals in each group. First group was given only 1% Na-CMC suspension. Second group was orally administered Ibuprofen (370 mg/kgBB) in a 1% Na-CMC suspension. Third group was given Ibuprofen ester derivative (450 mg/kgBB) in a 1% Na-CMC suspension by mouth.

### 2.3. Ethical Approval

This study was approved by the department ethical committee at its meeting on July 27, 2016 under a project entitled "Structural Modification and Ulcerogenic Test of Ibuprofen Compound on Male Rats" An approval certificate was obtained bearing reference number 846/H4.8.4.5.31/PP36-KOMETIK/2016.

### 2.4. Drug Administration

Drug was administered into each animal once daily for 5 days. The first group was treated with suspension of Na-CMC 1%, the second group was given ibuprofen 370 mg / kgBB and the third group was treated with ester compound as much as 450 mg / kgBB. After 5 days, stomach acid pH, number of ulcer and ulcer condition and gastric histopathology were observed.

### 2.5. Anesthesia, Surgery and Data Analysis

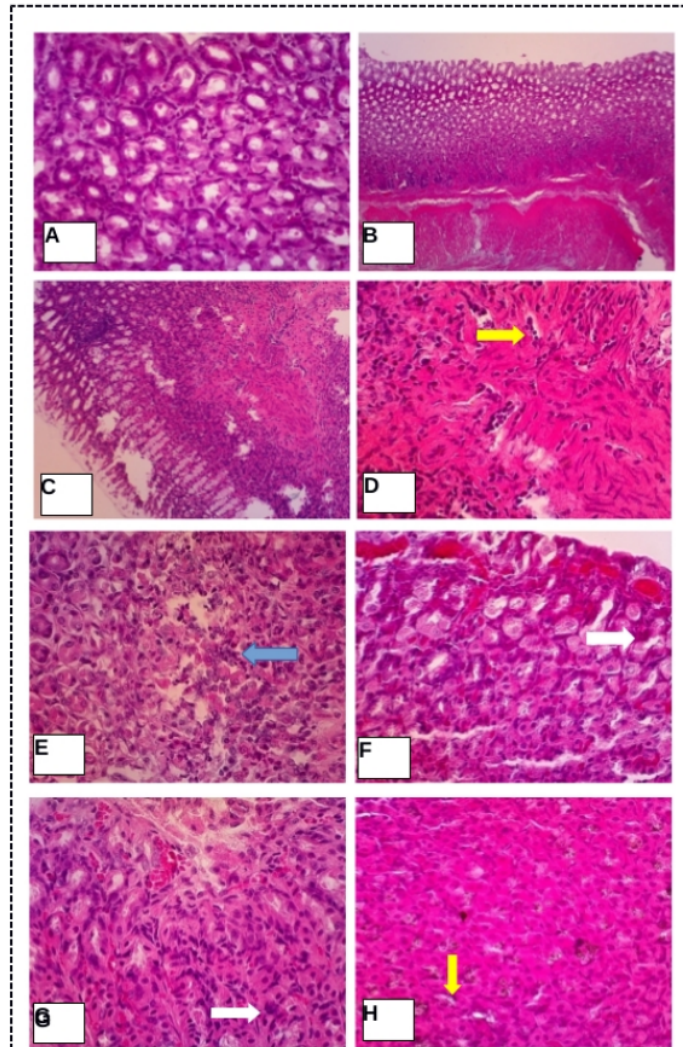
Rats were anesthetized using ether (50 mg/kg), their consciousness were recovered within 30 min while their gastric juices were allowed to accumulate for 4 h. Animals were euthanized by cervical dislocation. Each animal's stomach was dissected out for histological analysis. On histological studies, the number of ulcer is counted. Ulcer scoring was carried out according to previously described methods. The data represent mean  $\pm$  SD (n = 6), \*P<0.05, \*\*P<0.01, \*\*\*P<0.001, one way ANOVA followed by Dunnett's post hoc analysis.

## 3. Results and discussion

### 3.1 Gastric ulcerogenic activity

We observed a significant reduction (P <0.05) in the number of ulcer with the treatment of ibuprofen ester conjugate compared to the treatment of ibuprofen. The high number of ulcers occurring in the ibuprofen group was affected by the mechanism of action of ibuprofen in inhibiting cyclooxygenase enzymes (COX-1 and COX-2) [8]. The presence of free carboxylic groups in the molecular structure of ibuprofen is considered as the cause of gastric ulcer in the region of rats' gastric corpus [9]. The experiments of gastric ulcerogenic in rats revealed that there was no ulcer in the control group. This result was comparable with the group who received ibuprofen ester conjugates (Table 1). However, the

stomach of rats given ibuprofen exhibited higher number of ulcer with larger diameter of ulcer (Table 1).



**Figure 1.** Macroscopic representation of each group's stomach, (A, B) the control group (C, D, E, F) the ibuprofen-treated group (G, H) the ibuprofen ester-group. Image Magnification : (A) 10x10; (B) 40x10; (C)10x10; (D) 40x10; (E) 40x10; (F) 40x10; (G) 40x10; (H) 40x10.

**Table 1.** The number and diameter of ulcers (mean  $\pm$  SD) in the control, in the ibuprofen-treated and in the ibuprofen ester-treated groups.

(Mean $\pm$ SD)	Control (%)	Ibuprofen (%)	Ester (%)
The number of ulcer	0.00 $\pm$ 0.00	2.60 $\pm$ 1.82	0.40 $\pm$ 0.55
The diameter of ulcer	0.00 $\pm$ 0.00	1.06 $\pm$ 0.62	0.40 $\pm$ 0.56

Figure 1 (A and B) show the histology of the stomach in the control group. Figure 1 (C, D, E and F) show the histology of the ibuprofen-administered group in which the blue arrow indicates the presence of necrosis, the black arrow indicates the formation of connective tissue, the yellow arrow indicates the presence of hemorrhage, and the white arrow indicates congestion. Figures 1 (G and H) show the histology of the ibuprofen ester-administered group where the yellow arrow indicates the presence of a hemorrhage and the white arrow indicates congestion. Other mechanisms such as COX-1 inhibition also damage some gastric mucosal defenses that cause decreased mucosal blood flow, mucus secretion and bicarbonate. Inhibition of thromboxane synthesis (TxA<sub>2</sub>) in COX-1 can also produce bleeding. The inhibition of COX-2 causes the endothelial adhesion of leukocytes in microcirculation that contribute to ulcer formation [10].

### 3.2 Histopathological Analysis

Histopathological examination with the treatment of ibuprofen esters showed hemorrhage in some parts of the stomach and congestion appeared in some deposited sections due to bleeding in the stomach whereas with ibuprofen suffered from necrosis, hemorrhage and gastric congestion compared to the control. Ulcers commonly cause capillary damage in the mucosa, hemorrhage and necrosis. Acute ulcer is more common in the stomach than the duodenum. Gastric disorders are also common is gastritis. Gastritis is inflammation of the gastric mucosa including erosive gastritis caused by irritation, gall bladder reflux and pancreas, hemorrhagic gastritis, infectious gastritis and gastric mucosal atrophy [11].

The mechanism of mucosal damage to gastritis results from an imbalance between digestive factors, such as gastric acid and pepsin with mucus, bicarbonate and blood flow production. The incidence of gastritis due to infection of a foreign agent or chemical irritation begins with congestion and hemorrhage in the gastric mucosa. The damage is then immediately followed by changes in the epithelium, hemorrhage, edema and epithelial surface erosion. Damage to epithelial cells may allow for back diffusion of H<sup>+</sup> ions to the mucosa.

Histopathological examination showed that ibuprofen administration showed the presence of necrosis in some parts of the stomach and the formation of connective tissue due to necrosis process and the presence of bleeding and congestion. Congestion is the increase of fluid in a place that occurs due to passive processes caused by fluid flow falls out of the tissues, for example on venous damage. Passive congestion is a decrease in the amount of blood flowing from the area. In areas with inflammation congestion may occur [11].

### 4. Conclusion

Hemorrhage and congestion existed in the stomach of the group given ibuprofen ester. Necrosis, hemorrhage and congestion were detected in the stomach of the group given ibuprofen. In conclusion, the administration of ibuprofen esters on rats had a smaller risk of ulcerogenic effects than that of received ibuprofen.

**Acknowledgement**

We would like to acknowledge the Ministry of Research and Technology Higher Education of Indonesia for the financial support.

**References**

- [1] Sweetman SC 2009 *Martindale The Complete Drug Reference* 36<sup>th</sup> edition (London, UK: Pharmaceutical Press) pp 75-76
- [2] Ricciotti E and FitzGerald GA 2011 Prostaglandins and Inflammation. *Arterioscler Thromb. Vasc. Biol.* **31** 986–1000
- [3] Zhao X, Tao X, Wei D and Song Q 2006 Pharmacological Activity and Hydrolysis Behaviour of Novel Ibuprofen Glucopyranoside Conjugates. *European Journal of Medicinal Chemistry* **41** 1352–1358
- [4] Rifai Y 2018 Search for Glioma direct binding site of alkaloid using protein-ligand ant system. *Asian Journal of Pharmaceutical and Clinical Research* **11** 65-67
- [5] Rautio J 2011 *Prodrug Strategies in Drug Design, Prodrugs and Targeted Delivery: Towards Better ADME Properties* (Weinheim: Wiley-VCH) pp 703-729
- [6] Walsangikar SD, Bhatipa NM and Bhatima MS 2013 Structural Modification and Evaluation of Ibuprofen to Overcome GI Side Effects. *Int J APS BMS* **2** 138-148
- [7] Maag H 2007 *Prodrugs of Carboxylic Acids* 2<sup>nd</sup> edition (The USA: AAPS Press) pp 3-29
- [8] McEvoy GK 2004 *AHFS Drug Information* (The USA: Amec Soc of Health System) pp 24-30
- [9] Halen PK, Murumkar PR, Giridhar R and Yadav MR 2009 Prodrug Designing of NSAIDs. Review. *Mini-Reviews in Medicinal Chemistry* **9** 124-139
- [10] Wallace JL 2008 Prostaglandins, NSAIDs, and Gastric Mucosal Protection: Why Doesn't the Stomach Digest Itself?. *Physiol Rev.* **88** 1547–1565
- [11] Greaves P 2000 *Histopathology of Preclinical Toxicity Studies Interpretation and Relevance in Drug Safety Evaluation* 2<sup>nd</sup> edition (Amsterdam: Elsevier) pp 8-10

# Gastroulcerogenic Evaluation of Ibuprofen Ester Conjugates

---

## ORIGINALITY REPORT

---

**12%**

SIMILARITY INDEX

**9%**

INTERNET SOURCES

**7%**

PUBLICATIONS

**3%**

STUDENT PAPERS

---

## MATCH ALL SOURCES (ONLY SELECTED SOURCE PRINTED)

---

2%

★ [mdpi-res.com](http://mdpi-res.com)

Internet Source

---

Exclude quotes  On

Exclude matches  < 5 words

Exclude bibliography  On